



Day Chiropractic

3758 SE 122nd Avenue
Portland, OR 97236-3405

Phone: 503/760-7572

David A. Day, D.C., P.C.
Chiropractor

www.DayChiropractic.com

Headache #1 Video Summary:

Your Name: _____ Date: ___/___/___

Big problem: Headaches have “chiropractic” written all over them. Over ____ million Americans suffer from headaches every day.

Problems with medical approach:

- Assumption is that the cause of headache is in the head – blood vessel diameter changes, tumors, etc. Study of HMO in the US – 89 consecutive HA cases had MRI or CT scan – not one of them found anything wrong. They also looked at patients with malignant tumors during that same year period – only 5 % had headaches as their primary complaint.
- Medication is based on paradigm of tension vs. migraine. This is probably the wrong direction to go in most cases.
- Medicines for headaches can themselves cause headaches
- Consumer reports – in 1994 surveyed patients, over ___% of all headache patients were dissatisfied (higher rate of dissatisfaction than any other condition surveyed).

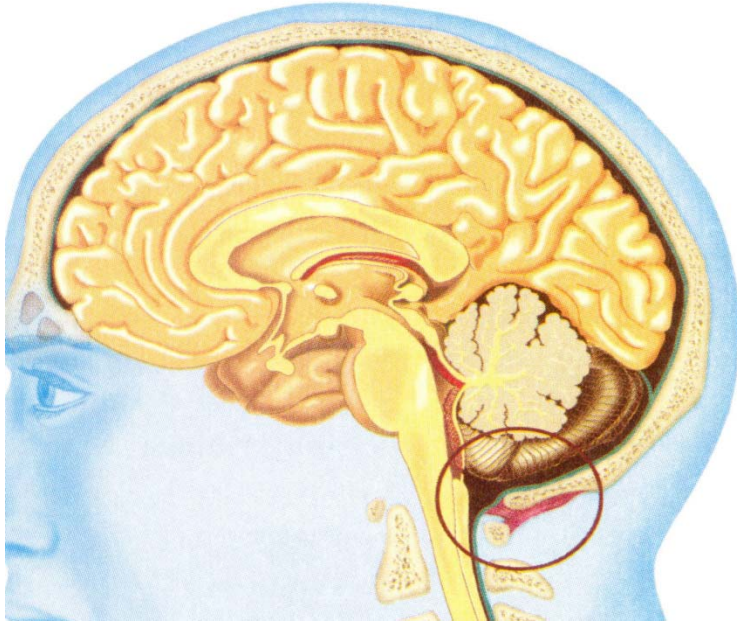
Chiropractic:

- We have found that most of the time (as much as ___ %) headache sufferers can obtain significant relief or elimination of their headaches with chiropractic care.
- New classification for headache: “_____”. The doctors that first coined that term estimate as many as _____ million out of the 80 million have this type of headache.
- 2 new discoveries: 1. Joints in the neck can trigger pain in the trigeminal nerve distribution (side of head and face, behind eye) 2. Rectus Capitus Posterior Minor which is a muscle in the back of your head that attaches to the lining of your spinal cord!

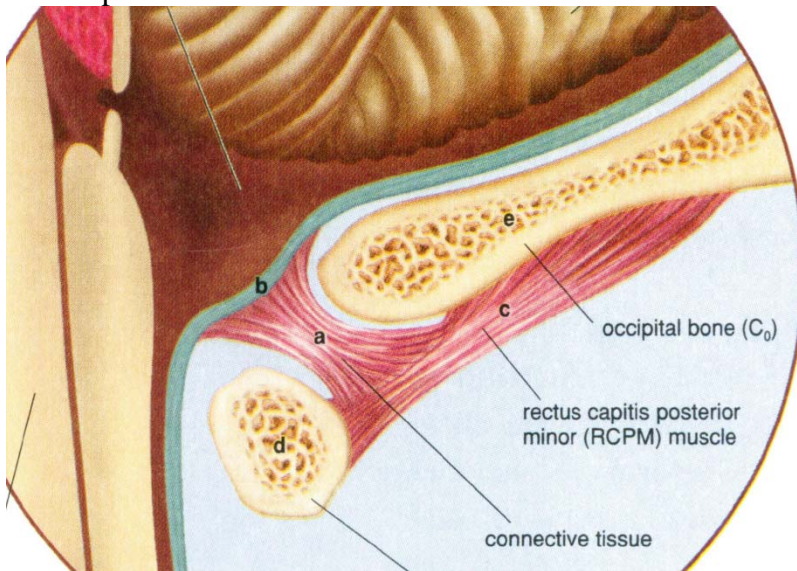
1. Dr. Nicolai Bogduk - _____ joints and surrounding structures send information into the spinal cord and up towards the brain, where they spill over into nerve cells of the Trigeminal nerve (____th cranial nerve). The body can't tell that the pain is in the neck, it thinks it is coming from the face, behind the eye or even the side of the head. Injections as low as C ___ relieved the headache!

2. Dental Anatomists - Rectus Capitus Posterior Minor (_____) muscle has a tissue bridge between the muscle and the Dura Mater between the skull and C1.

Wide view of the Rectus Capitus Posterior Minor tissue extension to the Dura Mater:



Close-up of the muscle attachment:



More research links: <http://www.chiro.org/LINKS/headache.shtml>